

ORIGINAL RESEARCH

Field treatment of facial and scalp actinic keratoses with photodynamic therapy: Survey of patient perceptions of treatment satisfaction and outcomes

Dai T Tran and Robert Salmon

Illawarra Dermatology and Laser Clinic, Wollongong, New South Wales, Australia

ABSTRACT

Background: Diffuse field change with actinic keratoses (AK) is a ubiquitous skin disease in Australia, with potential for malignant transformation. We report on 35 consecutive patients who had field therapy with single session photodynamic therapy (PDT) using 1 h incubation time for 5-aminolevulinic acid (5-ALA) or 3 h for methyl-aminolevulinate (MAL).

Methods: We retrospectively telephone surveyed our patient cohort regarding their satisfaction and perceptions of the effectiveness, side-effect profile and benefits of PDT. We also reviewed all patients' notes for significant side-effects.

Results: Sixty-nine per cent ($n = 24/35$) of patients responded to the telephone survey; 66% ($n = 16/24$) of the respondents reported good clearance of AK and claimed a good cosmetic outcome. All respondents reported moderate or severe pain (42% and 58%, respectively) during the illumination phase. Twenty per cent of all patients treated had suffered from one or more of the following side-effects: pustulation; severe erythema; and skin erosions.

Conclusions: Overall, our results compared favourably with previously published studies using 5-ALA or MAL PDT. However, our patient cohort experienced a greater side-effect profile. This may have been due to our patients having greater disease burden compared to other studies and possibly due to our use of topical retinoids prior to PDT in selected patients.

Key words: actinic keratoses, field therapy, patient satisfaction, photodynamic therapy.

INTRODUCTION

Australia has the highest rate of skin cancer in the world.¹ The Australian mortality incidence from non-melanoma skin cancer (NMSC) between 1998 and 2005 had an average of 382 deaths per year.²

Premalignant actinic keratosis (AK) is a ubiquitous disorder among fair complexioned Australians. The northern Australian population of Nambour, Queensland (latitude 26°S), has a prevalence of 44% in men and 37% in women.³ While in the south of Australia, Maryborough, Victoria (latitude 37°S) the prevalence is lower, at 19%.⁴

AK is not a benign disease, the majority of SCC are thought to arise from AK in 60%–72% of cases.^{5–7} Hence, it is thought by some authorities, that AK is SCC *in situ* from its inception.⁸ The general rate of AK transformation to invasive SCC is 0.001% to 19%,^{5,7,9} and for organ transplant recipients it is said to be up to 40%.¹⁰ The metastatic rates for SCC on the head and neck are much greater than those on the trunk and limbs.^{11,12} There is no specific method of predicting when AK may progress to SCC, so it is prudent to treat AK early, particularly those on the head and neck, to avoid disfigurement, morbidity and possible mortality. Accordingly, the European guidelines recommend that AK should be treated.¹⁰

A number of treatment modalities for AK are well established, and include cryotherapy, curettage and electrocautery, topical fluorouracil cream 5%, imiquimod cream 5%, diclofenac sodium 3% gel in a 2.5% hyaluronic acid base, and chemical peels. All treatments for AK however, have their own side-effect profile including pain, inconvenience,

Abbreviations:

5-ALA	5-aminolevulinic acid
AK	Actinic keratoses
DVA	Department of Veterans Affairs
LN	Liquid nitrogen
MAL	Methyl aminolevulinate
NMSC	Non-melanoma skin cancer
PDT	Photodynamic therapy
PpIX	Protoporphyrin IX
WC	WorkCover insurance

Correspondence: Dr Dai T Tran, 25 Osborne Street, Wollongong, NSW 2500, Australia. Email: drdt@hotmail.com

Dai T Tran, FRACGP, Robert Salmon, FACD.

Conflict of interest: The authors declared that no conflict of interest exists.

Submitted 11 February 2011; accepted 27 April 2011.

poor cosmetic result both during and after treatment, and high cost. All these factors hinder compliance.¹⁵

Photodynamic therapy (PDT) is a relatively new therapeutic modality for treatment of AK. The relatively high cost and labour intensiveness of PDT makes it suitable, mostly, for patients with large areas of field change. PDT uses methyl aminolevulinate (MAL) or 5-aminolevulinic acid (5-ALA) which are both prodrugs producing protoporphyrin IX (PpIX) intracellularly via the porphyrin cascade (Fig. 1). PpIX, when exposed to certain light wavelengths, reacts with oxygen to produce free radicals which cause cellular injury and death. The precise mechanisms underlying the efficacy of topical PDT in the treatment of NMSC are not fully known and may involve apoptosis and necrosis of cells via membrane lipid peroxidation, mitochondrial injury, microcirculatory disruption and the general sequelae of overwhelming exogenous oxidative stress.^{14,15}

PDT protocols can range from a single treatment session, to two sessions separated by 1 to 4 weeks rest interval, with

further repeated treatment as necessary.^{14,17} At Illawarra Dermatology and Laser Clinic we perform single session PDT field therapy with 1 h incubation periods using 5-ALA or 3 h incubation periods using MAL. The aims of the treatment protocol are to reduce the risk of SCC developing from AK, and to improve cosmesis and clearance of background AK. As PDT has also been shown to be effective against early non-melanoma skin cancers, field therapy may clear these lesions at a subclinical stage.¹⁸ The reduction in background AK should make it easier for future detection and management of skin cancers on 'a cleaner slate'. Furthermore, a single session treatment was aimed to reduce costs for our patients, many of whom are retired and/or on a fixed income. Twelve months after we started the program, we telephoned patients to evaluate the efficacy and acceptability of our treatment regime compared to standard liquid nitrogen therapy which all patients had undergone previously.

METHODS

Patients with diffuse facial or scalp AK were selected to have PDT field therapy using 160 mg/g MAL cream (Metvix, Galderma International, Paris, France) or generic compounded 20% 5-ALA solution that we obtained from Australian Custom Pharmaceuticals Pty Ltd (Sydney, NSW, Australia). The company claims that this 5-ALA solution is stable for up to 6 months with refrigeration. Due to the relatively high cost of MAL, treatment with this compound was reserved for patients covered by the Department of Veterans Affairs (DVA) or WorkCover insurance (WC). Neither of these two groups of insurers will currently meet the costs of PDT using 5-ALA, a schedule 4 drug on the Therapeutic Goods Administration list of medications.^{19,20}

The protocol for PDT was as follows:

- All patients had an initial consultation where the PDT process and clearance rates were discussed. They were also given brochures on PDT to take home and read. Costs were discussed and written informed consent was obtained.
- A topical retinoid, adapalene or tretinoin 0.05% cream, was applied nightly as tolerated for 2 weeks prior to treatment on patients with extensive hyperkeratotic AK.
- On the day booked for PDT, the areas to be treated were washed with any available soap free cleanser for 2 min. Gentle skin surface debridement was performed by gently scrubbing with cotton gauze soaked in 70% ethanol. Thick hyperkeratosis scales were gently removed with a curette.
- 5-ALA solution was applied and covered with an opaque mask fashioned from tissue paper pads with soft polyethylene laminated backing. (Fig. 2) Alternatively a 1 mm thick layer of MAL cream, as recommended by the manufacturer,²¹ was applied and occluded with soft polyethylene plastic wrap and covered with the same mask as outlined above.

A waiting period of 1 h was allowed to elapse before the 5-ALA patients were examined under a Woods' lamp by the

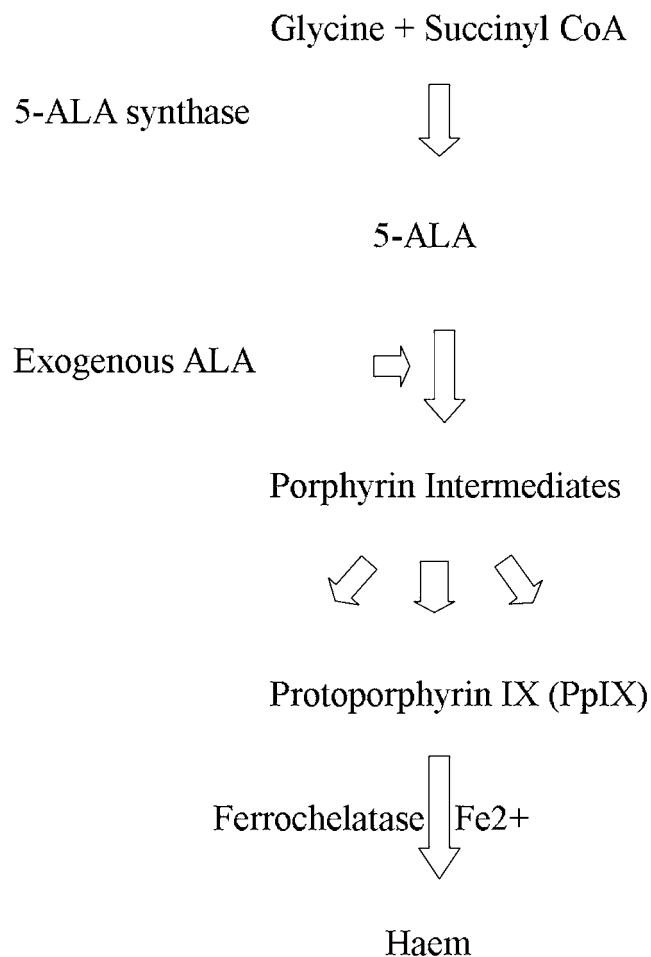


Figure 1 When methyl aminolevulinate is applied topically, the molecule is demethylated to 5-aminolevulinic acid (5-ALA) and administration of 5-ALA artificially increases endogenous synthesis of protoporphyrin IX (PpIX). The conversion of PpIX into haeme is a slow reaction, cells therefore accumulate great concentrations of PpIX.¹⁶

treating dermatologist, looking for a uniform bright pink fluorescence in the areas of AK, indicating accumulation of PpIX. Surface fluorescence intensity was observed as: 1, mild; 2, moderate; 3, strong; and 4, very intense. If there was insufficient fluorescence (1–2), the opaque dressing was




Figure 2 An opaque mask is fashioned using a template as shown. The paper material for the mask has a soft polyethylene laminated backing. This backing is placed against the patient's skin. The patient is advised to stay in a dimly lit room for the duration of occlusion.

reapplied and the process repeated 30 min later. For all scalp and facial fields, the exposure time was either 60 or 90 min. A standard incubation time of 3 h was used for all MAL patients.

- For both groups, the skin was then washed with a soap free cleanser and tap water.
- Illumination was with non coherent red light with peak average wavelength 630 (± 5) nm from a standard light source (Aktelite, Photocure ASA, Oslo, Norway) placed 5 cm from the skin for 7 min.

The standard analgesia provided for all patients consisted of a cold water spray and a chilled air blower (ArTek Air, ThermoTek Inc., Flower Mound, TX USA.). Further analgesia was offered as required, consisting of intramuscular tramadol, oral dextropropoxyphene and paracetamol tablets, regional nerve blocks, and local aesthetic infiltration for particularly painful areas or individual lesions.

From Aug 2009 to Nov 2010, 35 patients with diffuse AK were treated with PDT. Patients were contacted by telephone 3 to 16 months following PDT and asked to respond to a basic questionnaire. (Table 1) They were surveyed on the treatments they had received for their AK, namely PDT and liquid nitrogen (LN) cryotherapy. Participation was voluntary. Participants were asked to rate the treatments on discomfort, effectiveness, speed of recovery, affordability, overall satisfaction and recommendation to others.

RESULTS

The patients in this study typically had marked and diffuse facial actinic keratosis. All patients had a history of NMSC. The areas treated were typically on the head (Table 2). Sixty-nine per cent of patients ($n = 24/35$) were reachable by telephone for the survey.

Pain was the most significant problem during illumination. Forty-two per cent ($n = 10/24$) and 58% ($n = 14/24$) of respondents reported moderate or severe pain, respectively. Compared to 71% of respondents ($n = 17/24$) reporting moderate pain with LN cryotherapy and 30% ($n = 7/24$) reporting severe pain.

Table 1 Facial/scalp actinic keratosis photodynamic therapy (PDT) survey questionnaire

Please rate your pain level during PDT illumination, light treatment from 1–10		
Mild (1–4)	Moderate (5–7)	Severe (8–10)
Please rate the effectiveness of PDT in clearing your sunspots		
Very effective	Somewhat effective	Not at all effective
Please rate the effectiveness of PDT compared to liquid nitrogen		
More effective	Equally effective	Not at all effective
Please rate the speed of recovery following PDT compared to liquid nitrogen		
Faster	Equal	Slower
Please rate the cost/affordability of PDT compare with liquid nitrogen		
Barely affordable	Affordable	Very economical
Please rate your overall satisfaction with PDT		
Very satisfied	Somewhat satisfied	Not at all satisfied
Would you recommend PDT to other people?		
Yes	No	

Table 2 Areas treated with photodynamic therapy (PDT)

Areas treated with PDT	Number of patients treated
Forehead	14
Temple	5
Cheeks	11
Nose	7
Full face	3
Lip	2
Scalp	11

Twenty per cent ($n = 7/35$) of patients were unable tolerate field PDT illumination without a local aesthetic nerve block. Nerve blocks provided inadequate pain relief for two of those patients and they were given an additional intramuscular analgesic injection of tramadol. Fifty-seven per cent ($n = 4/7$) of these seven patients mentioned above had topical retinoid prior to treatment.

Patients' perception of healing time was equivocal, with 58% ($n = 14/24$) reporting faster recovery and 42% ($n = 10/24$) reporting slower recovery when compared to localised LN cryotherapy.

With regard to efficacy, 50% ($n = 12/24$) of patients felt that PDT was very effective at clearing their AK. The rest rated clearance as somewhat effective. One patient did not think his AK cleared up at all; that patient had the preconception that PDT would completely eliminate all his AK.

Regarding affordability of PDT treatment, when excluding the four patients with DVA and WC insurance, 70% ($n = 14/20$) rated it as barely affordable and 30% ($n = 6/20$) as affordable. DVA and WC patients' treatment costs were fully covered by their respective insurance providers. The average cost of medications for our field 5-ALA PDT cohort was \$60 and that of field MAL PDT cohort was \$4000, bearing in mind that a 2 g tube of Metvix cream covers 20 cm² (field size: 4 × 5 cm) at \$495 per tube. Most of our cohort were pensioners or retirees, with a mean age of 66 (age range 36–89).

Overall, 66% ($n = 16/24$) of patients reported higher satisfaction following PDT compared with LN cryotherapy, with the laser being 16% ($n = 4/24$); 66% ($n = 16/24$) would recommend PDT to other patients.

Those who would not recommend field PDT fell into two groups. Firstly, patients who had experienced moderate to severe side-effects, namely pustulation, severe erythema, skin erosions (Figs 3,4) and severe pain. Seven of the 35 patients experienced these complications, with four of those seven patients (57%, $n = 4/7$) having had pretreatment with a topical retinoid. Another cohort, 33% ($n = 8/24$), who would not recommend PDT to other patients were those who experienced less than expected clearance of their AK relative to cost, pain and complications involved.

DISCUSSION

PDT has been reported to be effective therapy for AK.^{17,22–24} However, in Australia, the cost associated with PDT can be prohibitive as it is not subsidized by Medicare Australia on the Medicare/Pharmaceutical Benefit Schedule. Some

practitioners perform PDT on two separate occasions for any given field, as this means each treatment can be less aggressive, and therefore less painful, and the overall AK clearance rate may be higher. As we felt that performing two cycles of PDT would be financially inconvenient for our cohort, we opted for a more aggressive approach, using an incubation period of between 60 and 90 min for 5-ALA lotion on the face and scalp, followed by 7 min of red light illumination.

We chose our 5-ALA skin incubation times to take advantage of the slight differential penetration of 5-ALA of normal and AK-affected skin,²⁵ and the apparent successes of previous studies.^{17,22–24} However, our patient group experienced significant adverse affects of skin erythema, crusting, erosion, pustulation and moderate to severe pain. Not unexpectedly, we observed that those with greater side-effects of severe skin crusting, erosion or pustulation had greater clearance of their AK.

Most of our patient cohort had severe and diffuse involvement of AK. Their skin thus may have had poorer barrier function, and hence reduced selectivity between lesional and non-lesional skin for 5-ALA prodrug penetration.²⁶ Additionally our use of topical retinoic acid as a keratolytic may further have reduced skin barrier function.²⁷ This reduction in barrier function is important because 5-ALA and MAL had been previously reported to have selective uptake within neoplastic lesions when applied *in vivo*. However, a recent publication has suggested that this selectivity was not demonstrable on cells cultured with 5-ALA. No significant differences were found in cellular PpIX content when comparing lesional and non-lesional cells derived from AK-affected skin.^{25,28} Selectivity was hypothesized to be due to differences in the integrity of the stratum corneum between normal skin and that involved with AK. Curetting individual AK prior to general field application of 5-ALA or MAL or directed individual lesional application of topical keratolytics could overcome this non-selectivity.

Pain was the most important issue with our patients undergoing PDT. All patients surveyed reported moderate to severe pain. This is in contrast to previous publications which stated high tolerability in their patient groups.^{22–24} Perhaps this was due to those authors using alternative light sources of lower penetrating wavelengths, for example the BLU-U blue light illuminator (Wilmington, MA, USA), generating 10j/cm² with average light wavelengths of 400 nm. Other investigators have used intense pulse light or laser as their light source.²⁹ The red light we used generates 37j/cm² at 8 cm from the skin and produces light with average wavelength of 630 nm, giving rise to deeper skin penetration of greater than 2 mm compared to less than 1 mm at 400 nm,^{29,30} hence it may have greater effect on thicker AK and general non-selective tissue damage. Greater light penetration may also affect the cutaneous pain nerve receptors to a greater degree. In contrast to MAL, 5-ALA may be transported into nerve fibres and this may be one of the explanations for the greater pain experienced.³¹ Furthermore, our cohort was severely sun damaged, and this may lead to more severe complications.

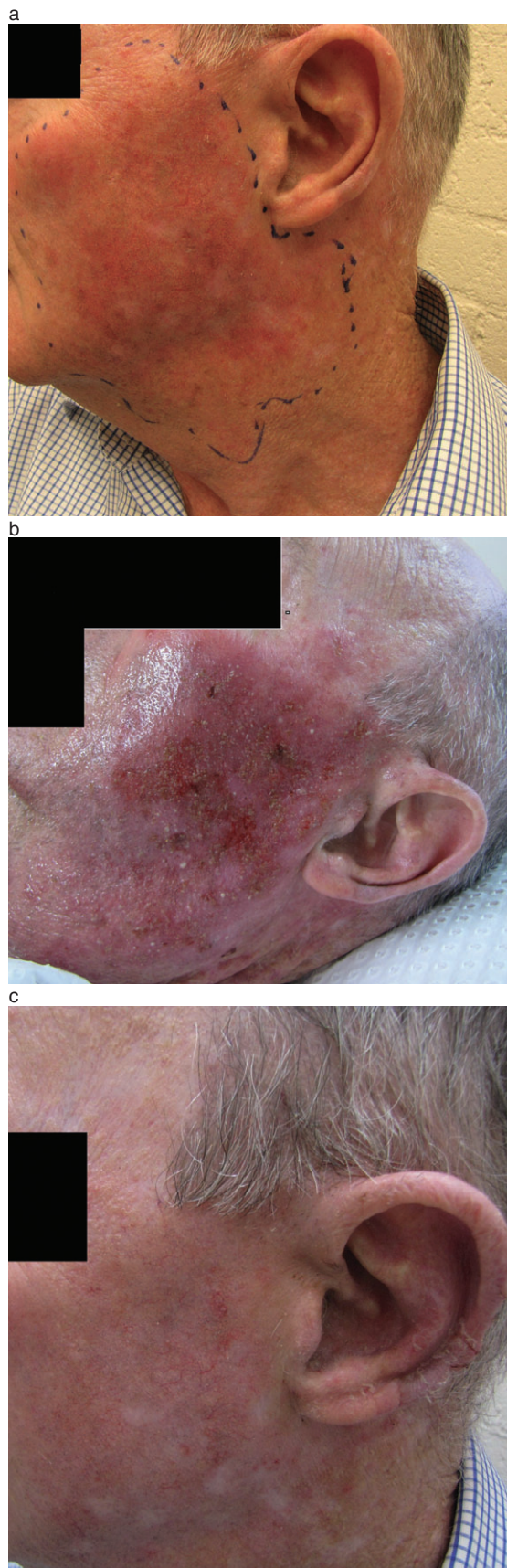

Figure 3 (a) Pre-5-aminolevulinic acid photodynamic therapy (5-ALA-PDT) patient. Notice the hypopigmented macules from extensive liquid nitrogen (LN) cryotherapy. (b) Two days post 5-ALA-PDT the patient experienced marked erythema with small areas of erosion and pustulation. (c) Eight months post 5-ALA-PDT there is still a significant clinical improvement which is difficult to achieve with LN cryotherapy alone.

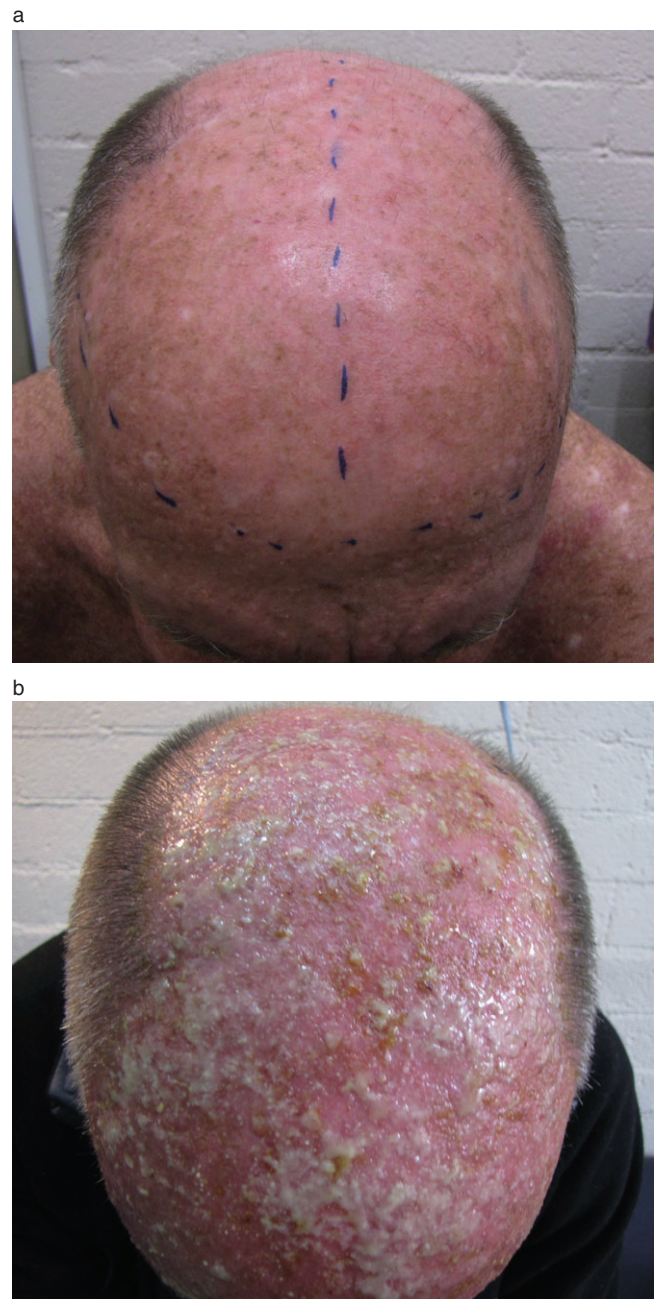


Figure 4 An example of pustulation in a patient with marked actinic keratosis pretreated with retinoic acid followed by methyl aminolevulinate photodynamic therapy. (a) pre-PDT. (b) five days post PDT.

Although only four patients had field MAL PDT, three of these experienced severe pain requiring regional local anaesthesia and one experienced infection requiring oral cephalixin.

Overall, 66% of respondents reported good clearance of AK and claimed a good cosmetic outcome. However, we may be underreporting the efficacy of PDT due to the small sample size. Despite this limitation, both of these outcomes concur with other studies.^{22–24} Improved cosmesis is not unexpected, as the permanent hypopigmentation caused by LN cryotherapy is avoided (Fig. 2). Skin rejuvenation, via new collagen formation, following the generalized phototoxic effect of PDT may also enhance the overall cosmetic result.³²

CONCLUSION

Overall our patient group reported a very satisfactory outcome some months following PDT therapy, as compared to LN cryotherapy for AK. There was an added bonus of overall subjective cosmetic improvement. The biggest barrier to future retreatment with PDT or a positive recommendation to others patients were the side-effects of significant intra-illumination pain, post illumination phototoxic effects, and relatively high cost. If these adverse factors could be overcome, or adequately managed, then we would encourage widespread adoption of PDT field treatment for facial and scalp AK.

Changing certain aspects of our management may help reduce morbidity with this therapy. We feel that it may be advantageous to treat patients at an earlier stage in the development of their disease, so that there are fewer pre-malignant cells to absorb the prodrug, leading to less overall pain from the phototoxic reaction. Avoiding the use of pretherapy topical retinoids may lead to less damage to normal cells, by maintaining normal barrier function in uninvolved skin. Finally, using nerve blocks for treatment of both forehead and scalp fields as a routine, prior to irradiation, rather than employing them when pain has already commenced, may improve overall patient comfort.

REFERENCES

1. Staples M, Marks R, Giles G. Trends in the incidence of non-melanocytic skin cancer treated in Australia 1985–95: are primary prevention programs starting to have an effect? *Int. J. Cancer* 1998; **78**: 144–8.
2. Non-melanoma skin cancer General practice consultations, hospitalization and mortality Australian Institute of Health and Welfare and Cancer Australia. Sep 2008 Available from URL: <http://www.aihw.gov.au/publications/can/nmsc/nmsc.pdf>. (Accessed 12 Jan 2011.)
3. Green A, Beardmore G, Hart V *et al.* Skin cancer in a Queensland population. *J. Am. Acad. Dermatol.* 1988; **19**: 1045–52.
4. Marks R, Foley P, Goodman G *et al.* Spontaneous remission of solar keratoses: the case for conservative management. *Br. J. Dermatol.* 1986; **115**: 649–55.
5. Marks R, Rennie G, Selwood TS. Malignant Transformation of solar keratoses to squamous cell carcinoma. *Lancet* 1988; **9**: 795–7.
6. Czarnecki D, Meehan CJ, Bruce F *et al.* The majority of cutaneous squamous cell carcinomas arise in actinic keratoses. *J. Cutan. Med. Surg.* 2002; **6**: 207–9.
7. Criscione VD, Weinstock MA, Naylor MF *et al.* Actinic keratoses. *Cancer* 2009; **115**: 2523–30.
8. R wert-Huber J, PATE LMJ, FORSCHNE RT *et al.* Actinic keratosis is an early in situ squamous cell carcinoma: a proposal for reclassification. *Br. J. Dermatol.* 2007; **156**: 8–12.
9. Glogau RG. The risk of progression to invasive disease. *J. Am. Acad. Dermatol.* 2000; **42**: 23–4.
10. Stockfleth E, Ferrandiz C, Grob JJ. Development of a treatment algorithm for actinic keratoses: a European Consensus. *Eur. J. Dermatol.* 2008; **18**: 651–9.
11. Basal cell carcinoma, squamous cell carcinoma (and related lesions). A guide to clinical management in Australia. Cancer Council Australia and Australian Cancer Network, Sydney. 2008. Available from URL: <http://www.cancer.org.au/File/BasalcellcarcinomaSquamouscellcarcinomaGuideNov2008Final.pdf>. (Accessed Jan 2011.)
12. Joseph MG, Zulueta WP, Kennedy PJ. Squamous cell carcinoma of the skin of the trunk and limbs: the incidence of metastases and their outcome. *Aust. N. Z. J. Surg.* 1992; **62**: 697–701.
13. Rivard J, Ozog D. Henry Ford Hospital dermatology experience with Levulan Kerastick and blue light photodynamic therapy. *J. Drugs Dermatol.* 2006; **5**: 556–61.
14. Braathen LR, Szeimies RM, Basset-Segu n N *et al.* Guidelines on the use of photodynamic therapy for nonmelanoma skin cancer: an international consensus. *J. Am. Acad. Dermatol.* 2007; **56**: 125–45.
15. Nowis D, Makowski M, Stok osa T. Direct tumor damage mechanisms of photodynamic therapy. *Acta Biochemi. Pol.* 2005; **52**: 339–52.
16. Ericson MB, Wennberg AM, Larko O. Review of photodynamic therapy in actinic keratosis and basal cell carcinoma. *Ther. Clin. Risk. Manag.* 2008; **4**: 1–9.
17. Tarstedt M, Rosdahl I, Berne B. A Randomized Multicenter Study to Compare Two Treatment regimens of Topical Methyl Aminolevulinate (Metvix)-PDT in Actinic Keratosis of the Face and Scalp. *Acta Derm. Venereol.* 2005; **85**: 424–8.
18. Apalla Z, Sotiriou E, Chovarda E *et al.* Skin cancer: preventive photodynamic therapy in patients with face and scalp cancerization. A randomized placebo-controlled study. *Br. J. Dermatol.* 2010; **162**: 171–5.
19. Available from URL: [https://www.ebs.tga.gov.au/servlet/xmlmillr6?dbid=ebs/PublicHTML/pdfStore.nsf&docid=103294&agid=\(PrintIngredient\)&actionid=1](https://www.ebs.tga.gov.au/servlet/xmlmillr6?dbid=ebs/PublicHTML/pdfStore.nsf&docid=103294&agid=(PrintIngredient)&actionid=1). (Accessed 17 Mar 2011.)
20. Available from URL: <http://www.tga.gov.au/pdf/scheduling-decisions-1102.pdf>. (Accessed 17 Mar 2011.)
21. Center for drug evaluation and research. Application number 21-415. Sep 2001. Available from URL: http://www.accessdata.fda.gov/drugsatfda_docs/nda/2004/021415s000_Metvixia_BioPharmr.pdf. (Accessed Jan 2011.)
22. Freeman M, Vinciullo C, Francis D *et al.* A comparison of photodynamic therapy using topical methyl aminolevulinate (Metvix ) with single cycle cryotherapy in patients with actinic keratosis: a prospective, randomized study. *J. Dermatol. Treat.* 2003; **14**: 99–106.
23. Touma D, Yaar M, Whitehead S *et al.* A trial of short incubation, broad-area photodynamic therapy for facial actinic keratoses and diffuse photodamage. *Arch. Dermatol.* 2004; **140**: 33–40.
24. Shaffeburg M. Treatment of actinic keratosis with sequential use of photodynamic therapy and imiquimod 5% cream. *J. Drug Dermatol.* 2009; **8**: 35–9.

25. Fritsch C, Homey B, Stahl W *et al.* Preferential relative porphyrin enrichment in solar keratoses upon topical application of delta-aminolevulinic acid methylester. *Photochem. Photobiol.* 1998; **68**: 218–21.
26. van den Akker JT, Holroyd JA, Vernon DI *et al.* Chronic UVB exposure enhances in vitro percutaneous penetration of 5-aminolevulinic acid in hairless mouse skin. *Lasers Surg. Med.* 2004; **34**: 141–5.
27. Waller JM, Dreher F, Behnam S *et al.* Keratolytic properties of benzoyl peroxide and retinoic acid resemble salicylic acid in man. *Skin Pharmacol. Physiol.* 2006; **19**: 283–9.
28. Smits T, Van Laarhoven AIM, Staassen A. Induction of protoporphyrin IX by aminolaevulinic acid in actinic keratosis, psoriasis and normal skin: preferential porphyrin enrichment in differentiated cells. *Br. J. Dermatol.* 2009; **160**: 849–57.
29. Alexiades-Armenakas M. Laser-mediated photodynamic therapy. *Clin. Dermatol.* 2006; **24**: 16–25.
30. Barolet D, Boucher A. Radiant near infrared light emitting Diode exposure as skin preparation to enhance photodynamic therapy inflammatory type acne treatment outcome. *Lasers Surg. Med.* 2010; **42**: 171–8.
31. Wiegell SR, Stender IM, Na R *et al.* Pain Associated With Photodynamic therapy using 5-Aminolevulinic Acid or 5-Aminolevulinic Acid Methylester on Tape-Stripped Normal Skin. *Arch. Dermatol.* 2005; **139**: 1173–7.
32. Fink-Puches R, Soyer HP, Hofer A *et al.* Long-term clinical follow-up and histological changes of superficial non-melanoma skin cancers treated with topical delta-aminolevulinic acid photodynamic therapy. *Arch. Dermatol.* 1998; **134**: 821–6.